

# HTLV-1 infection and disease with special reference to the dermatological manifestations: a critical review

AI Bhigjee<sup>1\*</sup>, CH Lela<sup>2</sup>

## Abstract

### Introduction

Human T-cell lymphotropic virus type 1 was initially isolated from a patient with cutaneous T-cell lymphoma. Since then, it has been known to be associated with three main disorders, namely adult T-cell leukaemia/lymphoma, human T-cell lymphotropic virus type 1-associated myelopathy and infective dermatitis associated with human T-cell lymphotropic virus type 1. This review examines the dermatological manifestations in detail.

### Discussion

Skin manifestations range from xerosis to infective dermatitis associated with human T-cell lymphotropic virus type 1 and lymphoma. The prototype of skin involvement is infective dermatitis associated with human T-cell lymphotropic virus type 1, which occurs in childhood. It is characterised by weeping, erythematous and scaly lesions affecting the face, scalp, retroauricular and flexural areas of the body. Infection with *Staphylococcus aureus* and haemolytic streptococcus leads to these lesions, which improve only after prolonged antibiotic therapy. Infective dermatitis associated with human T-cell lymphotropic virus type 1 often remits at puberty, but may be a forerunner of human T-cell lymphotropic virus type 1-associated myelopathy or adult T-cell leukaemia/lymphoma. The main differen-

tial diagnosis is atopic eczema, an important consideration, as treatment and prognosis are different. A peculiar unexplained feature of infective dermatitis associated with human T-cell lymphotropic virus type 1 is that it occurs in certain ethnic groups, it is common in Caribbean and Sub-Saharan Africa, but almost unheard of in Japanese infected individuals.

### Conclusion

Skin involvement occurs in up to 70% of human T-cell lymphotropic virus type 1-infected patients, including otherwise asymptomatic human T-cell lymphotropic virus type 1 carriers. Owing to its varied dermatological manifestations, it is an important consideration in the differential diagnosis in a number of skin disorders occurring in patients living in human T-cell lymphotropic virus type 1-endemic areas.

### Introduction

Retroviruses have the remarkable property of storing their genetic blueprint in the form of RNA. Once the virus enters the cell, its RNA is converted to DNA by the enzyme reverse transcriptase. This review briefly examines the epidemiology and characteristics of one of the retroviruses, the human T-cell lymphotropic virus type 1 (HTLV-1) and then discusses the dermatological manifestations associated with this virus in detail.

### Epidemiology

HTLV-1 is thought to be an old virus which originated in Africa, following multiple cross-species transmission from simians to humans some 27,000 years ago<sup>1</sup>. It continued to spread overland to Asia, by sea routes to the

Far East and by slave trade to America. The infection is now endemic in sub-Saharan Africa, Caribbean, South America, Japan, Melanesia and Middle East<sup>2</sup>. A curious observation is that within the endemic areas, the virus clusters in certain ethnic groups (Figure 1). The modes of transmission are sexual, blood transfusion and vertically from mother to child. Worldwide, the major mode is sexual with more effective transmission from male to female. The most efficient mode of transmission is blood transfusion, wherein the seroconversion rate may be as high as 60%. The probability of mother-to-child transmission is 18–30%, the main mode being breastfeeding.

### Virus characteristics

HTLV-1 is a cell-associated virus and is rarely detected in cell-free fluids. Its structure consists of two identical strands of 9032-nucleotide viral RNA, an inner protein core, an outer lipid bilayer derived from host cell membrane and a transmembrane protein which binds to the outer envelope glycoprotein. After attachment to the cell surface via the glucose receptor, the virus undergoes endocytosis and uncoating. The viral RNA is reverse transcribed to DNA, which moves to the nucleus, where it is integrated into the host chromosome. This proviral DNA undergoes the usual transcriptional and translational processes resulting in the production of viral proteins and formation of the viral particle.

### Disease associations

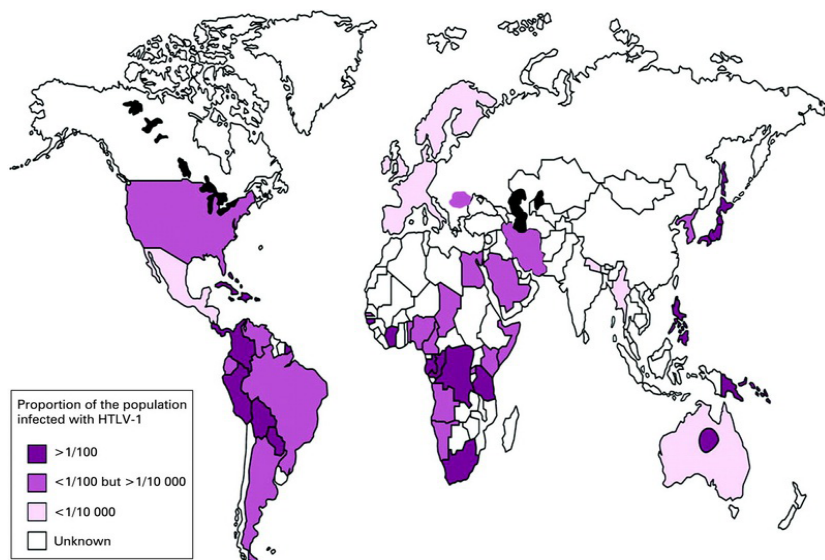
It is estimated that 15–20 million people are infected worldwide<sup>3</sup>. The virus causes a lifelong infection but

\* Corresponding author

Email: bhigjee@ukzn.ac.za

<sup>1</sup> Department of Neurology, Nelson R Mandela School of Medicine, University of KwaZulu-Natal, Durban, South Africa

<sup>2</sup> Division of Dermatology, Red Cross War Memorial Children's Hospital, University of Cape Town, Cape Town, South Africa



**Figure 1:** Representation of HTLV-1 seroepidemiology worldwide. Reproduced with permission from Cooper et al. *Pract Neurol*. 2009;9:16–26. HTLV-1, human T-cell lymphotropic virus type 1.

manifests as disease in only about 10% of infected individuals. The potential disease associations are listed in Table 1, the important ones being adult T-cell leukaemia/lymphoma (ATLL), HTLV-1-associated myelopathy (HAM/TSP) and infective dermatitis.

### Discussion

The authors have referenced some of their own studies in this review. These referenced studies have been conducted in accordance with the Declaration of Helsinki (1964) and the protocols of these studies have been approved by the relevant ethics committees related to the institution in which they were performed. All human subjects, in these referenced studies, gave informed consent to participate in these studies.

### Skin manifestations of HTLV-1 infection

Several skin manifestations have been observed in HTLV-1-infected individuals with ATLL or HAM/

TSP. Dermatologic lesions are also common in asymptomatic carriers (AC) (Table 2). In 1990, HTLV-1 was linked to a childhood eczema, named infective dermatitis associated with

HTLV-1 (IDH)<sup>4</sup>. Besides IDH, all other dermatologic manifestations reported in HTLV-1-infected individuals are non-specific<sup>5</sup>. Individuals infected by HTLV-1 are also more susceptible to other infections, such as tuberculosis and other bacterial infections, viral infections, and superficial mycoses. They may also present with parasitoses, such as scabies including crusted scabies and strongyloidiasis, with a high risk of disseminated strongyloidiasis<sup>6,7</sup>. Skin lesions in case of HTLV-1 infection may present as a warning sign for the diagnosis of infection or may be an indication of a complication associated with one of the clinical conditions linked to HTLV-1 infection. In this review, we outline the dermatologic manifestations that are associated with HTLV-1 infection.

### Dermatological lesions in asymptomatic carriers

Studies have documented that even ACs are not completely free of cutaneous lesions, bringing doubt to their asymptomatic status. Goncalves et al. reported a higher frequency of

HAM/TSP	
Adult T-cell leukaemia/lymphoma	
HTLV-1 associated uveitis	
Infective dermatitis associated with HTLV-1	
Miscellaneous	Polymyositis Polyneuropathy Hypertrophic pachymeningitis Cognitive impairment ANS dysfunction Uveitis Pneumonitis Arthritis Thyroiditis Delayed puberty and growth retardation Hyperinfection with strongyloides Crusted scabies
HTLV-1, human T-cell lymphotropic virus type 1; HAM/TSP, HTLV-1-associated myelopathy.	

Licensee OA Publishing London 2013. Creative Commons Attribution License (CC-BY)

**FOR CITATION PURPOSES:** Bhigjee AI, Hlela C. HTLV-1 infection and disease with special reference to the dermatological manifestations - a critical review. *OA Dermatology* 2014 Jan 18;2(1):1.

Table 2 Principal dermatologic lesions described in patients infected with HTLV-1

Characteristics of the infection	Dermatological lesions
ATLL	Macules, papules, plaques, tumours, erythroderma, dermatophytosis, scabies
HAM/TSP	Xerosis, acquired ichthyosis, palmar erythema, face erythema
IDH	Eczema predominant in flexures and scalp
AC	Xerosis, dermatophytosis, acquired ichthyosis, cutaneous candidiasis, seborrhoeic dermatitis, scabies

ATLL, adult T-cell leukaemia/lymphoma; IDH, infective dermatitis associated with HTLV-1; AC, asymptomatic carrier; HAM/TSP, human T-cell lymphotropic virus type 1-associated myelopathy.

dermatophytosis, seborrhoeic dermatitis and acquired ichthyosis in blood donors infected with HTLV-1 compared with non-infected individuals<sup>8</sup> Similarly, Maloney et al. noted seborrhoeic dermatitis in 25% of HTLV-1 carriers<sup>9</sup>. Infection by HTLV-1 results in dysregulation of the immune system, which makes infected individuals more susceptible to other infections and parasitosis that involves the skin such as scabies including crusted (Norwegian) scabies, bacterial skin infections and verruca vulgaris<sup>10,11</sup>. A study conducted in Salvador demonstrated a relationship between childhood eczema and infection by HTLV-1 in pregnant women<sup>12</sup>.

#### Skin lesions associated with human T-cell lymphotropic virus type 1-associated myelopathy

Reactional and persistent inflammatory dermatoses have been described in patients with HAM/TSP. Lenzi et al., on evaluating 32 cases with HAM/TSP, found cutaneous candidiasis, xerosis, and face and palmar erythema<sup>13</sup>. Some authors have considered these non-specific skin conditions to have a potential to progress to lymphoma and recommend skin biopsy of the representative lesions and histological follow-up of the patients<sup>10</sup>. The rationale for this suggestion is the finding of a lymphocytic infiltrate together with epidermotropism in

the same non-specific skin lesions in previous studies. Elevated serum levels of proinflammatory cytokines, such as TNF- $\alpha$ , have been reported in HTLV-1 carriers and in HAM/TSP patients<sup>14,15</sup>, which partially explain the occurrence and persistence of the inflammatory skin lesions in this group.

#### Skin lesions associated with adult T-cell leukaemia/lymphoma

Skin manifestations related to ATLL are better documented. According to clinical and laboratory data, ATLL is classified into smoldering, acute, chronic and lymphoma<sup>16</sup>. Bittencourt et al. recently proposed inclusion of another clinical type into the Shimoyama's classification, namely primary cutaneous tumoural<sup>17</sup>. This type is thought to be similar to the non-leukaemic smoldering type except for the presence of skin tumours and carries a worse prognosis. ATLL involves skin in 43–72% of cases<sup>18</sup>. Macular rash, patches, infiltrated plaques, papules, nodules, tumours or even erythroderma have been described in ATLL patients<sup>18,19</sup>. Tumours and nodules appear in more aggressive forms (acute, lymphomatous and primary cutaneous tumour)<sup>17</sup>. It is to be evaluated whether HTLV-1 is involved in the pathogenesis of the skin lesions or present in the skin because inflammatory cells containing the virus migrate to the skin.

#### Infective dermatitis associated with human T-cell lymphotropic virus type 1

The prototype of skin involvement following HTLV-1 infection is infective dermatitis associated with HTLV-1 (IDH). It may represent an early clinical marker for HTLV-1 infection and an indicator of an increased risk for developing other more devastating HTLV-1-associated diseases.

This disease was first described in 1966 by Sweet<sup>20</sup>. This author recognised 17 patients from Jamaica who had a peculiar type of eczema usually starting at the age of 2 years. Sweet noted that IDH lesions were scaly, exudative, and crusted and distributed on nostrils, ears, face, scalp and neck. He also observed a generalised and fine papular eruption and relapsing character of the lesions after withdrawal of antibiotics. A year later, Walshe documented a high incidence of *Staphylococcus* and/or  $\beta$ -haemolytic *Streptococcus* (BHS) infection in the nose and skin lesions of 25 cases of infective dermatitis<sup>21</sup>. It was Walshe who initially postulated that these children might be immunosuppressed. In 1990, for the first time, infective dermatitis was linked to HTLV-1 infection<sup>4</sup>. This relationship was later confirmed in a study in which 50 IDH patients were compared with 35 atopic dermatitis (AD) patients<sup>22</sup>. Only 5 out of 35 patients with AD were seropositive for HTLV-1. In both the groups, microbiologic studies showed frequent colonisation with *Staphylococcus aureus* and/or BHS. Patients with IDH were anaemic, had a higher white blood cell count and higher erythrocyte sedimentation rates compared with AD patients. They also had significantly higher levels of serum proteins and dermatopathic lymphadenopathy<sup>22</sup>. Cases from Africa were reported from Senegal<sup>23</sup> and South Africa<sup>24</sup>.

Following the initial reports of the association with HTLV-1, the disease was named IDH and the major and minor criteria for the diagnosis were

proposed<sup>22</sup>. The La Grenade's criteria were modified after a follow-up study of 42 IDH patients (Table 3)<sup>22,25</sup>. Following features are derived from La Grenade's original criteria:

- No reference was made in La Grenade's criteria for the frequency of the affected areas and as such, it is important to consider that the scalp is always involved. In Bahia, Brazil, besides the scalp, the retroauricular areas are also involved in 100% of the cases and in all patients at least three areas are affected.
- Crusting of the nostrils was a common finding; however, this feature was absent in some patients, and it is an inconstant feature.
- Rhinorrhoea is a common symptom in children caused by several other diseases.
- The relapsing nature of this disease with a prompt response to appropriate therapy and an equally rapid relapse if the drugs are withdrawn were present in all the patients and should be considered as an indispensable criterion for the diagnosis.
- The disease may begin later in childhood, and even in adulthood.
- In some patients who are serologically negative for HTLV-1, PCR should be performed.

#### *Infective dermatitis associated with human T-cell lymphotropic virus type 1 epidemiology*

Most of IDH cases have been documented in Jamaica, where the condition accounts for more than 10% of childhood dermatitis<sup>4,22,26,27</sup>. Interestingly, IDH is hardly reported in Japan, despite its high prevalence of HTLV-1 infection, implying that there are other factors at play, determining the development of skin disease following HTLV-1 infection.

#### *Clinical findings of infective dermatitis associated with human T-cell lymphotropic virus type 1*

IDH is a chronic and recurrent eczema occurring during childhood and

**Table 3** Criteria for the diagnosis of IDH

1. Presence of erythematous, scaly, exudative and crusted lesions of the scalp, retroauricular areas, neck, axillae, groin, paranasal and perioral skin, ears, thorax, abdomen and other sites
2. Crusting of nostrils
3. Chronic relapsing dermatitis with prompt response to appropriate therapy but prompt recurrence on discontinuation of antibiotics
4. Diagnosis of HTLV-1 infection (by serological or molecular biological testing)

Of the four major criteria, three are required for diagnosis, with mandatory inclusion of numbers 1, 3 and 4. To fulfil criterion 1, involvement of  $\geq 3$  of the sites is required, including involvement of the scalp and retroauricular areas.

HTLV-1, human T-cell lymphotropic virus type 1.

infrequently in adolescence or adulthood. The disease generally appears at 18 months, but may occur earlier. In a study, in 37% of the patients, the disease appeared at  $\leq 12$  months<sup>25</sup>. The frequency of IDH is greater among females<sup>22,25</sup>. It often begins with rhinitis, which is identified by the mother as 'cold'. This is followed by an oozing, weeping eruptions on many body areas<sup>26</sup>. The lesions are erythematous, scaly, frequently covered by yellow and fetid crusts always involving the face (Figure 2), scalp, retroauricular regions, flexures (Figure 3) and many other areas. As previously referred, affected individuals have to fulfil major criteria for a diagnosis to be made (Table 3). *S. aureus* and/or BHS are generally cultured from the anterior nares or skin lesions. The disease often remits at puberty<sup>25</sup>. The mean age of complete remission of IDH is 15 years, varying from 10 to 20 years<sup>25</sup>. However, IDH has been reported to persist until 23 years of age<sup>25</sup>. It may begin in adulthood with same clinical and immunohistochemical characteristics of IDH at early onset. However, only nine cases have been reported, all in females and four associated with HAM/TSP<sup>28</sup>. We have seen a 22-year-old female who presented with myelopathy and had scalp lesions (unpublished data). Comorbidities associated with IDH include scabies, corneal opacities, acquired

ichthyosis, chronic bronchiectasis, glomerulonephritis and lymphocytic interstitial pneumonitis<sup>23,25,26,29</sup>.

#### *Differential diagnosis*

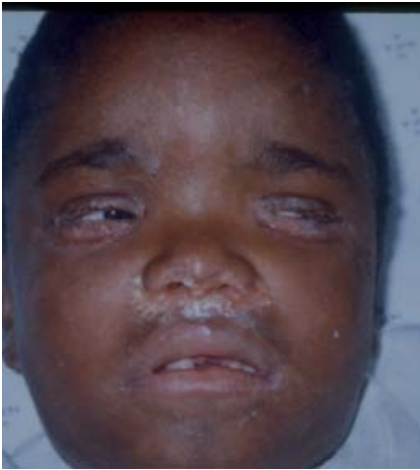The variable presentation of IDH, which may overlap with that of other dermatologic conditions, may lead to misdiagnosis. The most important differential diagnosis of IDH is AD<sup>22,25</sup>. A positive serology for HTLV-1, although helpful, is not the only criterion for diagnosis<sup>22</sup>. Both the diseases are susceptible to infection of the lesions by *S. aureus*. However, infection is significantly marked in IDH. A childhood onset is also shared by two conditions, but a significant difference between these conditions is the absence of a family history of atopy in IDH, a feature that characterises AD. Patients with both the conditions complain of pruritus, even though the intensity is much less in IDH<sup>25</sup>. On the other hand, the frequent findings of lesions in the antecubital and popliteal fossae may sometimes make it difficult to differentiate IDH from AD<sup>25,29</sup>.

#### *Infective dermatitis associated with human T-cell lymphotropic virus type 1 pathogenesis*

IDH pathogenesis is unknown, but thought to be multifactorial and shared among IDH, HAM/TSP and ATLL. IDH development is thought to be a result of an interplay between genetics, host's immune response

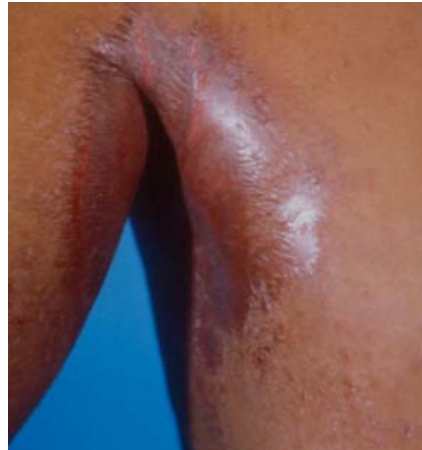Licensee OA Publishing London 2013. Creative Commons Attribution License (CC-BY)

**FOR CITATION PURPOSES:** Bhigjee AI, Hlela C. HTLV-1 infection and disease with special reference to the dermatological manifestations - a critical review. OA Dermatology 2014 Jan 18;2(1):1.



**Figure 2:** An IDH patient showing typical features on the face. Note the periorbital, perinasal and perioral eczematous eruptions. IDH, infective dermatitis associated with human T-cell lymphotropic virus type 1.

and environmental factors. Genetic factors are likely to be important in determining the host response to HTLV-1 infection, perhaps determining the carrier state or disease manifestation among those susceptible, following HTLV-1 infection. In Japan, where HTLV-1 is most prevalent, IDH is hardly ever reported, while other skin eruptions associated with HTLV-1 infection are observed in a significant proportion of Japanese population<sup>30</sup>. This indicates that other factors such as environmental factors, in addition to genetics, are likely to play a causative role. Similarities have been noted particularly between IDH and HAM/TSP, both being inflammatory manifestations of HTLV-1 infection. The basis for this proposal is the finding of elevated proinflammatory cytokines in IDH cultured cells, as has been noted in HAM/TSP<sup>15,31,32</sup>. The immune dysregulation associated with HTLV-1 infection likely facilitates chronic superinfection with SA and/or BHS, which additionally leads to chronic antigenic stimulation and persistent inflammation in the skin.



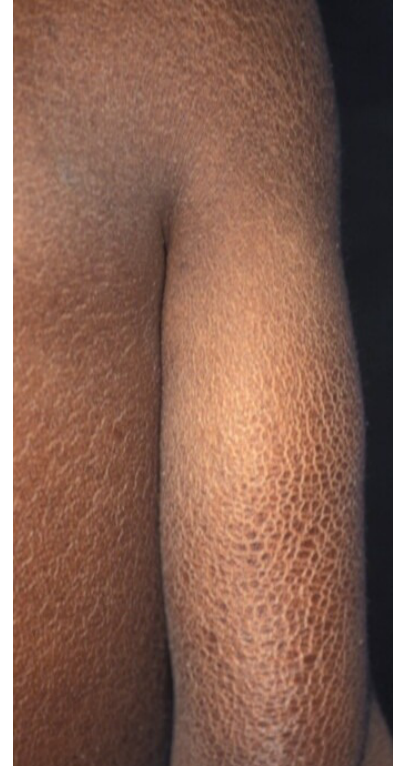**Figure 3:** Representation of the flexural eczematous lesion.

#### *Infective dermatitis associated with human T-cell lymphotropic virus type 1 treatment*

As IDH is always associated with bacterial infection, treatment of IDH is currently aimed at controlling infection by *S. aureus* and BHS. Treatment with sulphamethoxazole-trimethoprim (40 mg/kg/day of sulphamethoxazole and 8 mg/kg/day of trimethoprim) for 15 days and thereafter, one-half dose at night until the disease is controlled have been recommended<sup>29</sup>. Generally, the treatment lasts 3–12 months, depending on the response. A combination of prophylactic immunoglobulin and perhaps antiretroviral therapy needs to be investigated for possible use in the control of infection. Some investigators are also exploring the feasibility of an HTLV-1 vaccine<sup>3,33</sup>. It is recommended that these patients be carefully followed up with clinical and laboratory examinations.

#### **Xerosis and acquired ichthyosis**

Xerosis refers to dryness of the skin, while acquired ichthyosis presents as cutaneous xerosis together with polygonal thin flat squames of varied sizes principally in the extremities (Figure 4). About 67% of patients infected with HTLV-1,



**Figure 4:** Representation of acquired ichthyosis on the trunk and limb.

manifesting with HAM/TSP, have been shown to present with xerosis and acquired ichthyosis<sup>34</sup>. Carriers of HTLV-1 may also have acquired ichthyosis<sup>14</sup>. The cause of acquired ichthyosis in HTLV-1 infection is yet to be elucidated. Yamaguchi et al. have postulated that acquired ichthyosis in HTLV-1 is a consequence of the hypohydrosis commonly found in these patients<sup>35</sup>. It is also postulated that acquired ichthyosis may occur following an inflammatory lesion of the eccrine sudoriferous glands<sup>36</sup>.

#### **Seborrhoeic dermatitis**

In HTLV-1 carriers, a high rate of seborrhoeic dermatitis compared with uninfected individuals has been documented<sup>8,37</sup>. These investigators have also reported that eczema other than IDH was twice as common in infected children compared with the seronegative group<sup>37,38</sup>.

Licensee OA Publishing London 2013. Creative Commons Attribution License (CC-BY)

**FOR CITATION PURPOSES:** Bhigjee AI, Hlela C. HTLV-1 infection and disease with special reference to the dermatological manifestations - a critical review. OA Dermatology 2014 Jan 18;2(1):1.

## Infectious and parasitic dermatoses

Certain skin infections and parasitic infestations that manifest in the skin are well documented, including dermatophytoses, scabies and leprosy<sup>8,11,39,40</sup>. Severe forms of scabies are more strongly associated with HTLV-1 compared with HIV<sup>11</sup>. Other infections such as leprosy<sup>38,40</sup> and *Treponema pallidum* infections in HTLV-1 carriers<sup>41</sup> have also been described.

## Conclusion

Skin lesions in HTLV-1 infection are common and variable, and range from xerosis, ichthyosis, plaques, nodules parasitoses to IDH. IDH is regarded as the only cutaneous disease that is specific to HTLV-1 infection. Skin manifestations are noted in ACs or may be associated with either HAM/TSP or ATLL. Skin lesions associated with HTLV-1 infection may be a warning sign for progression to more devastating clinical conditions linked to HTLV-1 infection.

## Abbreviations list

AC, asymptomatic carrier; AD, atopic dermatitis; ATLL, adult T-cell leukaemia/lymphoma; BHS,  $\beta$ -haemolytic *Streptococcus*; HAM/TSP, HTLV-1-associated myelopathy; HTLV-1, human T-cell lymphotropic virus type 1; IDH, infective dermatitis associated with HTLV-1.

## References

1. Van Dooren S, Salemi M, Vandamme AM. Dating the origin of the African human T-cell lymphotropic virus type-i (HTLV-I) subtypes. *Mol Biol Evol.* 2001 Apr;18(4):661-71.
2. Verdonck K, Gonzalez E, Van Dooren S, Vandamme AM, Vanham G, Gotuzzo E. Human T-lymphotropic virus 1: recent knowledge about an ancient infection. *Lancet Infect Dis.* 2007 Apr;7(4):266-81.
3. de Thé G, Bomford R. An HTLV-I vaccine: why, how, for whom? *AIDS Res Hum Retroviruses.* 1993 May;9(5):381-6.
4. LaGrenade L, Hanchard B, Fletcher V, Cranston B, Blattner W. Infective

dermatitis of Jamaican children: a marker for HTLV-I infection. *Lancet.* 1990 Dec;336(8727):1345-7.

5. Nobre V, Guedes AC, Proietti FA, Stancioli E, Martins ML, Serufo JC, et al. [Dermatologic lesions in patients infected with the human T-cell lymphotropic virus type 1 (HTLV-1)]. *Rev Soc Bras Med Trop.* 2005 Jan-Feb;38(1):43-52.

6. Bastos Mde L, Santos SB, Souza A, Finkmoore B, Bispo O, Barreto T, et al. Influence of HTLV-1 on the clinical, microbiologic and immunologic presentation of tuberculosis. *BMC Infect Dis.* 2012 Aug;12:199.

7. Caskey MF, Morgan DJ, Porto AF, Gizzoza SP, Muniz AL, Orge GO, et al. Clinical manifestations associated with HTLV type I infection: a cross-sectional study. *AIDS Res Hum Retroviruses.* 2007 Mar;23(3):365-71.

8. Goncalves DU, Guedes AC, Proietti AB, Martins ML, Proietti FA, Lambertucci JR, et al. Dermatologic lesions in asymptomatic blood donors seropositive for human T cell lymphotropic virus type-1. *Am J Trop Med Hyg.* 2003 May;68(5):562-5.

9. Maloney EM, Nagai M, Hisada M, Soldan SS, Goebel PB, Carrington M, et al. Prediagnostic human T lymphotropic virus type I provirus loads were highest in Jamaican children who developed seborrheic dermatitis and severe anemia. *J Infect Dis.* 2004 Jan;189(1):41-5.

10. Rueda R, Blank A. HTLV-1 associated cutaneous manifestations. In: Cali: Feriva, editor. Zaninovic V. Zaninovic.; 1996.pp.212-22.

11. Brites C, Weyll M, Pedrosa C, Badaro R. Severe and Norwegian scabies are strongly associated with retroviral (HIV-1/HTLV-1) infection in Bahia, Brazil. *AIDS.* 2002 Jun;16(9):1292-3.

12. Bittencourt A, Brites C, Pereira Filho C, Dias NF, Vieira M. Linfoma/leucemia de células T associado ao HTLV-I (ATL) em criança e adolescente. *An Bras Dermatol.* 2001;76(Suppl 2):88.

13. Lenzi MER, Cuzzi-Maya T, Oliveira AL, Andrada-Serpa MJ, Araújo AQ. Dermatological findings of human T lymphotropic virus type 1 (HTLV-I)-associated myelopathy/tropical spastic paraparesis. *Clin Infect Dis.* 2003 Feb;36(4):507-13.

14. Carvalho EM, Bacellar O, Porto AF, Braga S, Galvao-Castro B, Neva F. Cytokine profile and immunomodulation in asymptomatic human T-lymphotropic virus

type 1-infected blood donors. *J Acquir Immune Defic Syndr.* 2001 May;27(1):1-6.

15. Nascimento MC, Primo J, Bittencourt A, Siqueira I, de Fátima Oliveira M, Meyer R, et al. Infective dermatitis has similar immunological features to human T lymphotropic virus-type 1-associated myelopathy/tropical spastic paraparesis. *Clin Exp Immunol.* 2009 Jun;156(3):455-62.

16. Shimoyama M. Diagnostic criteria and classification of clinical subtypes of adult T-cell leukaemia-lymphoma. A report from the Lymphoma Study Group (1984-87). *Br J Haematol.* 1991 Nov;79(3):428-37.

17. Bittencourt AL, da Graças Vieira M, Brites CR, Farre L, Barbosa HS. Adult T-cell leukemia/lymphoma in Bahia, Brazil: analysis of prognostic factors in a group of 70 patients. *Am J Clin Pathol.* 2007 Nov;128(5):875-82.

18. Bittencourt AL, Barbosa HS, Pimenta A, Farre L. A case of adult T-cell leukemia/lymphoma (ATL) with a survival of more than 13 years. *Acta Oncol.* 2008;47(5):981-3.

19. Bittencourt AL, Primo J, Oliveira MF. Manifestations of the human T-cell lymphotropic virus type I infection in childhood and adolescence. *J Pediatr (Rio J).* 2006 Nov-Dec;82(6):411-20.

20. Sweet RD. A pattern of eczema in Jamaica. *Br J Dermatol.* 1966 Feb;78(2):93-100.

21. Walshe MM. Infective dermatitis in Jamaican children. *Br J Dermatol.* 1967 Apr;79(4):229-36.

22. La Grenade L, Manns A, Fletcher V. Clinical, pathologic, and immunologic features of human T lymphotropic virus type-1 associated infective dermatitis in children. *Arch Dermatol.* 1998;134:439-44.

23. Mahe A, Meertens L, Ly F, Sow PS, Diop CT, Samb ND, et al. Human T-cell leukaemia/lymphoma virus type 1-associated infective dermatitis in Africa: a report of five cases from Senegal. *Br J Dermatol.* 2004 May;150(5):958-65.

24. Hlela C, Graham N, Bhigjee AI, Taylor GP, Khumalo NP, Mosam A. Human T cell lymphotropic virus type 1-associated infective dermatitis in KwaZulu Natal, South Africa. *BMC Dermatol.* 2013 Oct;13(1):11.

25. de Oliveira Mde F, Fatal PL, Primo JR, da Silva JL, Batista Eda S, Farré L, Bittencourt AL. Infective dermatitis associated with human T-cell lymphotropic

- virus type 1: evaluation of 42 cases observed in Bahia, Brazil. *Clin Infect Dis*. 2012 Jun;54(12):1714-9.
26. La Grenade L, Schwartz RA, Janniger CK. Childhood dermatitis in the tropics: with special emphasis on infective dermatitis, a marker for infection with human T-cell leukemia virus-I. *Cutis*. 1996 Aug;58(2):115-8.
27. La Grenade L. HTLV-1-associated infective dermatitis: past, present and future. *J Acquir Immune Defic Syndr Hum Retrovirol*. 1996;13:S46-9.
28. Maragno L, Casseb J, Fukumori LM, Sotto MN, Duarte AJ, Festa-Neto C, Sanches JA. Human T-cell lymphotropic virus type 1 infective dermatitis emerging in adulthood. *Int J Dermatol*. 2009 Jul;48(7):723-30.
29. Oliveira Mde F, Brites C, Ferraz N, Magalhaes P, Almeida F, Bittencourt AL. Infective dermatitis associated with the human T cell lymphotropic virus type I in Salvador, Bahia, Brazil. *Clin Infect Dis*. 2005 Jun;40(11):e90-6.
30. Sawada Y, Hino R, Hama K, Ohmori S, Fueki H, Yamada S, et al. Type of skin eruption is an independent prognostic indicator for adult T-cell leukemia/lymphoma. *Blood*. 2011 Apr;117(15):3961-7.
31. Goon PK, Biancardi A, Fast N, Igakura T, Hanon E, Mosley AJ, et al. Human T cell lymphotropic virus (HTLV) type-1-specific CD8+ T cells: frequency and immunodominance hierarchy. *J Infect Dis*. 2004 Jun;189(12):2294-8.
32. Lee R, Schwartz RA. Human T-lymphotropic virus type 1-associated infective dermatitis: a comprehensive review. *J Am Acad Dermatol*. 2011 Jan;64(1):152-60.
33. Manns A, Miley WJ, Wilks RJ, Morgan OS, Hanchard B, Wharfe G, et al. Quantitative proviral DNA and antibody levels in the natural history of HTLV-I infection. *J Infect Dis*. 1999 Nov;180(5):1487-93.
34. Milagres SP, Sanches JA Jr, Milagres AC, Valente NY. Dermatopathology Histopathological and immunohistochemical assessment of acquired ichthyosis in patients with human T-cell lymphotropic virus type I-associated myelopathy. *Br J Dermatol*. 2003 Oct;149(4):776-81.
35. Yamaguchi K. Human T-cell lymphotropic virus type 1 in Japan. *Lancet*. 1994;343:213-6.
36. Setoyama M, Mizoguchi S, Eizuru Y. Human T-Cell Lymphotropic Virus Type I Infects Eccrine Gland Epithelia. *Int J Cancer*. 1999 Mar;80(5):652-5.
37. Maloney EM, Wiktor SZ, Palmer P, Cranston B, Pate EJ, Cohn S, et al. A cohort study of health effects of human T-cell lymphotropic virus type I infection in Jamaican children. *Pediatrics*. 2003 Aug;112(2):e136-42.
38. Marsh BJ. Infectious complications of human T cell leukemia/lymphoma virus type I infection. *Clin Infect Dis*. 1996 Jul;23(1):138-45.
39. Blas M, Bravo F, Castillo W, Castillo WJ, Ballona R, Navarro P, et al. Norwegian scabies in Peru: the impact of human T cell lymphotropic virus type I infection. *Am J Trop Med Hyg*. 2005 Jun;72(6):855-7.
40. Glaser JB, Levis WR, Gruber T, Cabrera A, Poiesz BJ. Prevalence of human T cell lymphotropic virus (Htlv) types I and II and human immunodeficiency virus type 1 infections among persons with Hansen's disease in New York City. *J Infect Dis*. 1994 Oct;170(4):1007-9.
41. Carnaíba D Jr, Bittencourt A, Brites C. Atypical presentation of syphilis in an HTLV-I infected patient. *Braz J Infect Dis*. 2003 Aug;7(4):273-7.